

SHORT COMMUNICATION



Human herpes virus-8 in human immunodeficiency virus/acquired immunodeficiency syndrome - associated oral Kaposi's sarcoma

K. Badari Rao

Department of Oral Pathology & Microbiology, NSVK Sri Venkateshwara Dental College & Hospital, Bannerughatta, Bangalore, Karnataka, India

Keywords

Acquired immunodeficiency syndrome, human herpes virus-8, human immunodeficiency virus, oral Kaposi's sarcoma

Correspondence

Dr. K. Badari Rao, Department of Oral Pathology & Microbiology, NSVK Sri Venkateshwara Dental College & Hospital, Kariyappanahalli, Anekal Road, Bannerughatta, Bangalore - 560 083, Karnataka, India. Phone: +91-9902028816, Email: dr.badarirao@gmail.com

Received 05 April 2014; Accepted 04 July 2014

doi: 10.15713/ins.jcri.9

Abstract

Human herpes virus-8 (HHV-8), now called Kaposi's sarcoma-associated herpes virus (KSHV), as a probable causative agent of Kaposi's sarcoma (KS) was put forth when it was first detected in KS specimens in 1994. Since then, many investigators have confirmed the association of HHV-8 and human immunodeficiency virus/acquired immunodeficiency syndrome (HIV/AIDS) - associated KS. This study was done to review the original research aimed at assessing the presence of HHV-8 in HIV/AIDS-associated oral KS and other oral lesions.

Introduction

Kaposi's sarcoma (KS), named after the Hungarian physician Moricz Kaposi, is a common vascular tumor seen in human immunodeficiency virus (HIV) infected patients and is one of the acquired immunodeficiency syndrome (AIDS) defining illness. AIDS-associated KS frequently involves the mucocutaneous regions of the head and neck as primary sites, in approximately 10% of all HIV-infected patients and in about 20% of patients in the homosexual/bisexual risk group.^[1] The oral cavity is involved in 50-80% of these cases, with the mucosa of the hard and soft palate, gingiva, and tongue being the most common locations.^[1,2]

This study aims to review the original research articles for assessing the prevalence percentage of human herpes virus-8 (HHV-8) in HIV/AIDS-associated oral KS.

Materials and Methods

A MEDLINE search was done using the keywords Kaposi's sarcoma, oral Kaposi's sarcoma, HIV-associated oral KS, AIDS-associated oral KS, HHV-8, and Kaposi's sarcoma-associated

herpesvirus (KSHV). The purpose of the search was to obtain original research articles pertaining to this review. A total of 8 articles could be included in the study; case reports being excluded. The details of the articles included for this review are listed in Table 1.

Based on the articles reviewed, the study sample could be categorized into three groups i.e. samples from:

1. HIV-positive (HIV(+)) patients with oral KS.
2. HIV(+) patients with other oral lesions.
3. HIV-negative (HIV(-)) patients with other oral lesions.

Data entry and statistical analysis were performed using SPSS version 10.0.5[®]. Analysis of variance (ANOVA) was done to compare the prevalence percentage of HHV-8 in each group.

Results

The prevalence percentage of HHV-8 (Table 2 and Graph 1):

- 82% in Group 1 i.e., HIV(+) oral KS samples
- 23% in Group 2, i.e., HIV(+) other oral lesion samples
- 0% in Group 3, i.e., HIV(-) other oral lesion samples.

Table 1: Studies addressing the presence of HHV-8 in HIV/AIDS-associated oral KS

Title	Author(s)	Year	HHV-8 detection technique	Sample type	Study group	Sample size	HHV-8 positive samples	HHV-8 negative samples	HHV-8 prevalence percentage
KSHV in oral KS ^[1]	DiAlberti <i>et al.</i>	1996	PCR	Tissue	HIV(+) oral KS	11	5	6	45.5
Presence of HHV-like DNA sequence in oral KS ^[2]	Jin <i>et al.</i>	1996	PCR	Tissue	HIV(+) oral KS	3	3	0	100
					HIV(-) other oral lesions	74	0	74	0
Presence of human herpes-8 variants in the oral tissues of HIV-infected persons ^[3]	Di Alberti <i>et al.</i>	1997	PCR	Tissue	HIV(+) oral KS	11	5	6	45.5
					HIV(+) other oral lesions	14	11	3	78.8
					HIV(-) other oral lesions	20	0	20	0
Epstein-Barr virus and HHV-8 prevalence in HIV-associated oral mucosal lesions ^[4]	Webster-Cyriaque <i>et al.</i>	1997	PCR	Tissue	HIV(+) oral KS	3	3	0	100
					HIV(+) other oral lesions	26	0	26	0
Frequent detection of KSHV(HHV-8) DNA in saliva of HIV-infected men ^[5]	Koelle <i>et al.</i>	1997	PCR	Saliva	HIV(+) oral KS	10	7	3	70
KSHV-like DNA (KSHV/HHV-8) sequences in oral KS ^[6]	Flaitz <i>et al.</i>	1997	PCR	Tissue	HIV(+) oral KS	54	53	1	98.2
					HIV(+) other oral lesions	5	0	5	0
					HIV(-) other oral lesions	3	0	3	0
Transmissible KSHV (HHV-8) in saliva of men with a history of KS ^[7]	Vieira <i>et al.</i>	1997	PCR	Saliva	HIV(+) oral KS	3	3	0	100
Oral KS: A clinicopathologic study from South Africa ^[8]	Lager <i>et al.</i>	2003	PCR	Tissue	HIV(+) oral KS	45	44	1	97.8
					HIV(+) other oral lesions	7	1	6	14.3

HHV-8: Human herpes virus-8, HIV: Human immunodeficiency virus, AIDS: Acquired immunodeficiency syndrome, KS: Kaposi's sarcoma, KSHV: Kaposi's sarcoma-associated herpesvirus, DNA: Deoxyribonucleic acid, PCR: Polymerase chain reaction

The difference in prevalence percentage between the three groups was statistically significant ($P = 0.001$).

Discussion

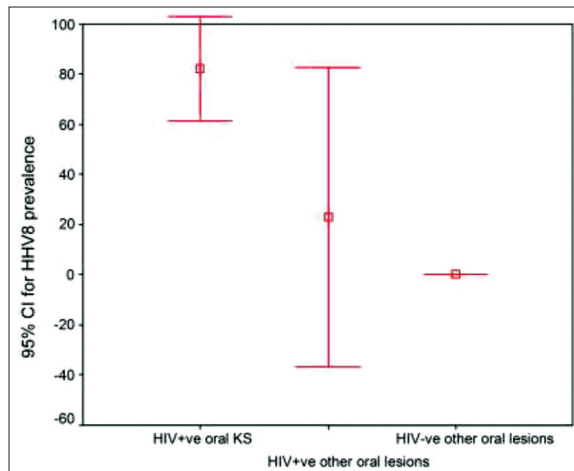
It is clear that HHV-8 is present in a high proportion of samples from HIV(+)/AIDS-associated oral KS^[1-8] when compared to other lesions (Table 2 and Graph 1). Studies documenting the presence of HHV-8 in AIDS-associated KS have been extended to include the other types of lesions in HIV(+)/AIDS patients^[3,4,6,8] and HIV(-) patients.^[2,3,6] Furthermore, all the oral KS samples have been found to contain HHV-8 DNA sequences,^[2,4,7] and the HHV-8 copy number is higher in the KS lesions than in other groups.^[8] These studies suggest that HHV-8 are not an opportunistic infectious agent related to AIDS. Although some non-KS tissues (other oral lesions) have been

Table 2: Mean prevalence percentage of HHV-8 in the three sample groups

Virus	Group	n	Mean	SD	P value
HHV-8	HIV(+) oral KS	8	82.1	24.8	0.001
	HIV(+) other oral lesions*	4	23.2	37.5	
	HIV(-) other oral lesions [#]	3	0.00	0.00	

*Viral/apthous ulcers, hairy leukoplakia, condyloma acuminatum, pyogenic granuloma, lymphoma. [#]Pyogenic granuloma, hemangioma, lymphangioma, papilloma, fibroma, pleomorphic adenoma, squamous cell carcinoma, verrucous carcinoma, dentigerous cyst. HHV-8: Human herpes virus-8, HIV: Human immunodeficiency virus, SD: Standard deviation, KS: Kaposi's sarcoma

found to contain HHV-8 sequences,^[3,8] most of these are from patients who either have cutaneous/systemic KS or are obtained from HIV(+) patients, and are likely to represent disseminated HHV-8 infection or be a result of small undetectable foci of



Graph 1: Prevalence percentage of human herpes virus-8 in the three sample groups

KS. Furthermore, all the studies have reported a lack of these sequences in HIV(-) other oral lesions, including a wide variety of vascular tumors, as well as inflammatory conditions that resemble KS in their cellular composition.^[2,3,6] Thus, it appears that HHV-8 sequences are present specifically in oral KS tissues, as well as in some other oral lesional tissues from patients with KS or at high risk for developing KS, such as HIV infection.

Further support for a causal association between HHV-8 and KS comes from the analysis of peripheral blood from patients with KS, or at high risk of developing KS, compared with other AIDS risk groups and HIV(-) individuals.^[9-11] In these studies, the presence of HHV-8 DNA sequences in the peripheral blood of many of these patients has preceded the development of KS, and the presence of HHV-8 DNA sequences in the peripheral or semen of KS(-) patients has predicted the subsequent appearance of KS lesions in some patients. Furthermore, serological assays have been developed and used to analyze many serum samples from various patients' population with or without KS.^[12-14] These studies have shown that the rate of HHV-8 seropositivity is high in HIV(+) patients with KS, and in HIV(+), KS(-), patients, but is much lower in HIV(-) individuals. An exception is finding of a high percentage HHV-8 seropositive individuals without KS, regardless of HIV status, suggesting that HHV-8 infection rates are higher in populations in whom KS is endemic. Furthermore, seroconversion to positivity for antibodies against HHV-8 related nuclear antigens has been found to occur before the clinical appearance of KS in a significant proportion of patients with AIDS-associated KS.^[15] Thus, the distribution of HHV-8 seropositivity indicates that HHV-8 varies among different populations but is not always ubiquitous. Studies so far suggest that HHV-8 is a sexually transmitted virus which closely relates with the risk for KS development, but also that there is a non-sexual route of transmission and that infection with HHV-8 does not necessarily imply the future development of KS.^[16]

Regardless of the incidence of HHV-8 infection in the general population, it is possible that the mechanisms operational in pathogenesis of the HHV-8 associated diseases could be explained by viral reactivation rather than primary infection. As in the case of other human herpesviruses, many conditions, including immunosuppression; immune stimulation; viral dose at the time of infection; and multiple genetic, environmental, and behavioral factors may cooperate in variable combinations in the pathogenesis of KS.

A different issue that has raised questions regarding the causal relationship between HHV-8 and KS is the observation that "KS" cell lines are negative for HHV-8, and cells cultured from KS lesions lose HHV-8 DNA after a few passages *in vitro*.^[17] However, *in situ* hybridization studies have shown the presence of HHV-8 in the spindle and endothelial cells, which are generally considered to represent the KS tumor cells.^[18] It remains to be determined whether HHV-8 is "lost" from these cells during culture or whether the cultured cells are different from the HHV-8 infected cells seen in the KS lesions.

Several issues regarding the incidence of HHV-8 infection and its relationship with the KS cells remain controversial and await further studies. However, the almost invariable presence of HHV-8 in all types of KS (virtually 100% of cases in most studies), its absence from other conditions that histologically resemble KS, its presence in the peripheral blood and tissues of patients with KS or at high risk for developing KS, and the patterns of immunoreactivity to HHV-8 antigens suggest an important, and most likely causal role for HHV-8 in the pathogenesis of KS.

Conclusion

An HHV-8 prevalence percentage of 82% in HIV(+) oral KS samples points to a possible causal role of HHV-8 in the multifactorial pathogenesis of HIV/AIDS-associated oral KS and HHV-8 infection as a high risk for the development of oral KS in HIV(+)/AIDS patients.

References

- DiAlberty L, Teo CG, Porter S, Zakrzewska J, Scully C. Kaposi's sarcoma herpesvirus in oral Kaposi's sarcoma. *Eur J Cancer B Oral Oncol* 1996;32B:68-9.
- Jin YT, Tsai ST, Yan JJ, Chen FF, Lee WY, Li WY, *et al.* Presence of human herpesvirus-like DNA sequence in oral Kaposi's sarcoma. A preliminary PCR study. *Oral Surg Oral Med Oral Pathol Oral Radiol Endod* 1996;81:442-4.
- Di Alberty L, Ngui SL, Porter SR, Speight PM, Scully CM, Zakrewska JM, *et al.* Presence of human herpesvirus 8 variants in the oral tissues of human immunodeficiency virus-infected persons. *J Infect Dis* 1997;175:703-7.
- Webster-Cyriaque J, Edwards RH, Quinlivan EB, Patton L, Wohl D, Raab-Traub N. Epstein-Barr virus and human herpesvirus 8 prevalence in human immunodeficiency virus-associated oral mucosal lesions. *J Infect Dis* 1997;175:1324-32.

5. Koelle DM, Huang ML, Chandran B, Vieira J, Piepkorn M, Corey L. Frequent detection of Kaposi's sarcoma-associated herpesvirus (human herpesvirus 8) DNA in saliva of human immunodeficiency virus-infected men: Clinical and immunologic correlates. *J Infect Dis* 1997;176:94-102.
6. Flaitz CM, Jin YT, Hicks MJ, Nichols CM, Wang YW, Su IJ. Kaposi's sarcoma-associated herpesvirus-like DNA sequences (KSHV/HHV-8) in oral AIDS-Kaposi's sarcoma: A PCR and clinicopathologic study. *Oral Surg Oral Med Oral Pathol Oral Radiol Endod* 1997;83:259-64.
7. Vieira J, Huang ML, Koelle DM, Corey L. Transmissible Kaposi's sarcoma-associated herpesvirus (human herpesvirus 8) in saliva of men with a history of Kaposi's sarcoma. *J Virol* 1997;71:7083-7.
8. Lager I, Altini M, Coleman H, Ali H. Oral Kaposi's sarcoma: A clinicopathologic study from South Africa. *Oral Surg Oral Med Oral Pathol Oral Radiol Endod* 2003;96:701-10.
9. Cannon MJ, Dollard SC, Black JB, Edlin BR, Hannah C, Hogan SE, *et al.* Risk factors for Kaposi's sarcoma in men seropositive for both human herpesvirus 8 and human immunodeficiency virus. *AIDS* 2003;17:215-22.
10. Marcelin AG, Gorin I, Morand P, Ait-Arkoub Z, Deleuze J, Morini JP, *et al.* Quantification of Kaposi's sarcoma-associated herpesvirus in blood, oral mucosa, and saliva in patients with Kaposi's sarcoma. *AIDS Res Hum Retroviruses* 2004;20:704-8.
11. Pauk J, Huang ML, Brodie SJ, Wald A, Koelle DM, Schacker T, *et al.* Mucosal shedding of human herpesvirus 8 in men. *N Engl J Med* 2000;343:1369-77.
12. Beyari MM, Hodgson TA, Cook RD, Kondowe W, Molyneux EM, Scully CM, *et al.* Multiple human herpesvirus-8 infection. *J Infect Dis* 2003;188:678-89.
13. Ablashi D, Chatlynne L, Cooper H, Thomas D, Yadav M, Norhanom AW, *et al.* Seroprevalence of human herpesvirus-8 (HHV-8) in countries of Southeast Asia compared to the USA, the Caribbean and Africa. *Br J Cancer* 1999;81:893-7.
14. Lampinen TM, Kulasingam S, Min J, Borok M, Gwanzura L, Lamb J, *et al.* Detection of Kaposi's sarcoma-associated herpesvirus in oral and genital secretions of Zimbabwean women. *J Infect Dis* 2000;181:1785-90.
15. Gao SJ, Kingsley L, Hoover DR, Spira TJ, Rinaldo CR, Saah A, *et al.* Seroconversion to antibodies against Kaposi's sarcoma-associated herpesvirus-related latent nuclear antigens before the development of Kaposi's sarcoma. *N Engl J Med* 1996;335:233-41.
16. Duus KM, Lentchitsky V, Wagenaar T, Grose C, Webster-Cyriaque J. Wild-type Kaposi's sarcoma-associated herpesvirus isolated from the oropharynx of immune-competent individuals has tropism for cultured oral epithelial cells. *J Virol* 2004;78:4074-84.
17. Flamand L, Zeman RA, Bryant JL, Lunardi-Iskandar Y, Gallo RC. Absence of human herpesvirus 8 DNA sequences in neoplastic Kaposi's sarcoma cell lines. *J Acquir Immune Defic Syndr Hum Retrovirol* 1996;13:194-7.
18. Staskus KA, Zhong W, Gebhard K, Herndier B, Wang H, Renne R, *et al.* Kaposi's sarcoma-associated herpesvirus gene expression in endothelial (spindle) tumor cells. *J Virol* 1997;71:715-9.

How to cite this article: Rao KB. Human herpes virus-8 in human immunodeficiency virus/acquired immunodeficiency syndrome - associated oral Kaposi's sarcoma. *J Adv Clin Res Insights* 2014;1:30-33.