



# Effectiveness of immediate loading protocol over conventional loading protocol in mandibular posterior region – A comparative prospective clinical study

G. Sajan Anand<sup>1</sup>, Muddasir Mohammed<sup>2</sup>, N. Manoj Kumar<sup>3</sup>, Phani Himaja Devi Vaaka<sup>1</sup>, Santosh Palla<sup>4</sup>

<sup>1</sup>Department of Oral and Maxillofacial Surgery, KIMS Dental College and Hospital, Amalapuram, Andhra Pradesh, India, <sup>2</sup>DDS program graduate, School of Dentistry, Indiana University, Indiana Polis, United States, <sup>3</sup>Department of Dentistry, Consultant Oral and Maxillofacial Surgeon, Apollo Hospitals, Nellore, Andhra Pradesh, India, <sup>4</sup>Sun Dental Care, Chennai, Tamil Nadu, India

## Keywords:

Conventional loading, dental implant, immediate loading, mandibular molars.

## Correspondence:

Dr. G. Sajan Anand, Department of Oral and Maxillofacial Surgery, KIMS Dental College and Hospital, Amalapuram, Andhra Pradesh, India. Phone: +91-9951017347  
E-mail: sajananand13@gmail.com

Received: 15 May 2020;

Accepted: 16 June 2020

doi: 10.15713/ins.jcri.298

## Abstract

**Background:** The topic of type of loading for a dental implant is currently in debate in dentistry for the past 2 decades. The study was aimed to compare the effectiveness of immediate loading protocol over conventional loading protocol in respect to bone loss and clinical parameters in mandibular posterior region which is common edentulous region having sufficient amount of bone.

**Materials and Methods:** A prospective clinical comparative study was on 20 participants assigned into Group A ( $n = 10$ ; delayed loading) and Group B ( $n = 10$ ; immediate loading). The participants were given Adin Touareg-S implants with titanium Grade 4 abutments conventionally in Group A and immediately in Group B. The outcomes evaluated were radiographic assessments marginal bone loss (MBL) and clinical soft-tissue assessments plaque index (PI), gingival index (GI), PI, and calculus index (CI). The unpaired t-test was used to compare the intergroup means of these parameters keeping the level of significance was set at  $P < 0.05$ .

**Results:** The MBL comparisons between Groups A and B have not yielded any significant differences ( $P > 0.05$  when compared from the 3<sup>rd</sup>, 6<sup>th</sup>, 9<sup>th</sup>, to 12<sup>th</sup> month) after implant placement. The mean value of PI, GI, and CI was not significantly different in the intergroup comparisons in the 3<sup>rd</sup>, 6<sup>th</sup>, 9<sup>th</sup>, and 12<sup>th</sup> month comparisons.

**Conclusion:** There were no significant differences in the MBL, GI, PI, and CI between the immediate and conventionally loaded implants in mandibular posterior region. The immediate loading can be considered as an alternative to conventional loading in the mandibular posterior region.

## Introduction

The replacement of lost natural teeth by endosseous implants has been considered to be the most significant advancement in the restorative dentistry. It is the standard care for reconstruction of edentulous arches due to favorable and high survival rate. The objective of implant-based treatment is to provide a controlled delivery of functional loads to osseous structures and maintain mechanical stability of the prosthesis.<sup>[1]</sup> The restoration dictates the implant position rather than osseous anatomy alone. It is important that the surgeon evaluates the role of implant position, shape, healing time, and the provisional restoration to achieve the objective of implant treatment.<sup>[1]</sup>

The present surge in the use of implants was initiated by Per Ingvar Branemark. He showed that titanium implants could become permanently incorporated within bone through his experiments. As per the original protocol stated by Branemark, dental implant placement is a two staged surgery with a submerged healing period of at least 3 months in jaw bone.<sup>[2,3]</sup> This time period allows the implant to osseointegrate and minimizes the risk of infection as the tissue around the implant is allowed to heal without any exposure to the external environment. Later, a second surgery is to be performed to connect the healing abutment.<sup>[2]</sup> However, during this intermediate period, there are chances of the development of various unwanted sequelae such as bone resorption (vertical and horizontal), gingival recession, and migration of tooth into the edentulous space can

occur. In addition, it is also associated with longer treatment duration, additional surgical procedure, and prolonged period of edentulousness.<sup>[4]</sup>

As the field of implantology is an ever evolving field, the traditional protocol for implant placement and loading has been constantly reevaluated with the introduction of various novel concepts such as implant placement in fresh extraction sockets, single-stage surgical approach, early loading, immediate non-functional loading, immediate functional loading, modifications in implant designs, modifications in surface topography, and changes in microstructure to a name a few.<sup>[4,5]</sup> The concept of immediate loading of implant has been developed. In 1990, it was first published that osseointegrated implants can be loaded early or immediately in mandibles of selected patients.<sup>[5]</sup> Although controversy exists regarding functional and non-functional loading, a meta-analysis showed that type of loading might not affect the survival of these dental implants.<sup>[6]</sup>

The topic of type of loading for a dental implant is currently in debate, due to evidence from studies<sup>[7-10]</sup> favoring it, as well as those studies<sup>[11-13]</sup> favoring against the concept. The immediate loading of implants aims at decreasing the treatment time with the placement of provisional prosthesis right on the day of surgery and also has various advantages over conventional loading protocol such as decreased bone resorption, decreased gingival recession, migration of tooth into the edentulous space, decreased treatment duration, and decreased period of edentulousness. Given the ambiguity, the study was aimed to compare the effectiveness of immediate loading protocol over conventional loading protocol in respect to boneless and implant survival rate.

## Materials and Methods

This was prospective clinical comparative study conducted in the oral and maxillofacial surgery, Narayana Dental College, Nellore, Andhra Pradesh, from May 2013 to February 2013. The study was approved by Institutional Review Board and Institutional Ethical Clearance before the start of the study. A written informed consent was obtained from all the participants, on fulfilling the inclusion criteria.

The sample was conveniently recruited with total of 20 participants assigned into Group A ( $n = 10$ ; delayed loading) and Group B ( $n = 10$ ; immediate loading). The sampling method employed was systematic sampling, that is, every case reporting to dental outpatient department was recruited if found suitable as per set criteria. The healthy participants aged between 20 and 50 years with partially edentulous arch in the posterior mandibular molar region (first or second molars) having good oral hygiene practices, adequate bone quality, and sufficient bone to accommodate implants (dimensions of implant: 10 mm long and 3.3 mm wide) were recruited for the study. The patients having surgical contradictions (bleeding-clotting disease spectrum), those who were uncontrolled diabetes, chronic/active smoker, pregnancy, poor oral hygiene,

patients on bisphosphonate drugs, pathological lesions in the molar region, those with psychiatric problems, severe clenching and bruxism, having active infection inflammation at proposed implant site, and those who were unwilling/uncooperative were excluded from the study.

The implant materials were Adin Touareg-S implants (Touareg™ S & OS - ADIN Dental Implant Systems Ltd., USA) with minimum dimensions – 3.3 mm wide and 10 mm long, maximum dimensions – 4.2 mm wide and 14 mm long. They were self-threaded and tapered. The abutments used were 1 mm to 4 mm (titanium Grade 4), the temporary crowns were acrylic while permanent crowns were metal ceramic.

## Preparative workup

The preparative workup included a detailed case history and clinical examination, intraoral photography, impression of upper and lower arches, and preparation of casts (die stone). The ridge mapping was performed on the cast to determine the available bone width buccolingually, mesiodistally, and occlusal clearance from the opposing natural teeth. Pre-operative orthopantomogram (OPG) and intraoral periapical radiographs were taken to determine the quality of the bone, long axis of the adjacent natural teeth both mesially and distally, and the distance from alveolar portion to the inferior alveolar neurovascular bundle. The length and height of the implant to be placed in the alveolar ridge were determined. A cure clear acrylic-based surgical template was fabricated over the edentulous region and pilot drill was employed to make access exactly at the proposed implant osteotomy site.

All the patients were operated under local anesthesia (2% lignocaine with 1:200,000 adrenaline). Patients were given inferior alveolar nerve block with lingual and long buccal nerve blocks. Infiltration of local anesthesia near the operative site is avoided. The surgical template was then placed over the edentulous ridge and pilot drill was to gain initial access at desired site. The crestal incision was given over the alveolar ridge with a 15 number B.P blade and full-thickness mucoperiosteal flap was elevated both buccally and lingually exposing the underlying alveolar ridge. The physiodispenser (settings: 1000 RPM; 40 NM. torque) was used for osteotomy after first pilot drill through previously marked site for the desired length of the implant. Once the osteotomy has been completed, thorough irrigation of the implant bed was done. The implant is then placed into the osteotomy site using wrench ratchet and tapped slowly until it is completely submerged into the bone and it is made sure that good primary stability has been achieved. Then, healing abutment is fixed over the implant in Group A patients and tray transfer is fixed over the implant in Group B patients. Mucosal closure is done with 3-0 Vicryl (absorbable sutures). Patients were advised to take only soft and semi-solid diet for 3 days after surgery and were kept on antibiotics and anti-inflammatory drugs for the next 5 days. The OPG and IOPA radiographs were taken through long cone technique immediately after implant placement. The patients were followed up regularly and were

instructed to use chlorhexidine mouth wash and gum paint massage twice daily for 4 weeks.

In Group A patients (delayed loading), healing abutments were placed immediately after the implant placements which were left to heal. Loading of the implants was done after 3 months. In Group B patients (immediate loading), tray transfers are placed immediately after implant placement and impressions were taken by closed tray technique using putty impression material, temporary acrylic crowns were given on the same day. These temporary crowns are replaced by metal ceramic crowns after 1 month. Patients were recalled on the 7<sup>th</sup> post-operative day, 1 month, 3 months, 6 months, 9 months, and 12 months. During every 3<sup>rd</sup> month, 6<sup>th</sup> month, 9<sup>th</sup> month, and 12<sup>th</sup> month follow-up, O.P.G and I.O.P.A were taken and gingival index (GI), plaque index (PI), and calculus index (CI) were recorded.

### Evaluation parameters

Both radiographic and clinical soft-tissue evaluation were done to evaluate the peri-implant bone levels.

#### Radiographic evaluation

Standardized periapical radiographs were exposed using paralleling technique with the help of XCP holders. The radiographs were digitized at a resolution of 100 dpi. These digitized images were used to measure marginal bone loss (MBL) around implants using commercially available software (Photoshop CS7.0; Adobe systems, USA). Images were magnified when needed to ensure accurate scoring. Radiographic bone loss measurements around the implant were done using two reference points; one was fixture abutment junction (F.A.J) and second was implant bone first contact point. Two lines are drawn passing through these points perpendicular to the long axis of the implant. The bone level was measured at mesial and distal aspect of the implant. Using the “measure tool” in the imaging software, the measured pixels were converted to millimeter and the distance between the two reference points was recorded. This was repeated at the 3<sup>rd</sup>, 6<sup>th</sup>, 9<sup>th</sup>, and 12<sup>th</sup> months after implant placement and bone loss was calculated at each interval.

#### Soft-tissue evaluation

The PI was measured as per standards (Silness and Loe in 1964). Likewise, the GI was also scored as per standard (Loe and Silness in 1963). These soft-tissue evaluation indices were included in the study as plaque-induced gingival inflammation along with calculus is considered as one of the etiological factors in peri-implant bone loss.

### Statistical tests

The data were tabulated and statistically analyzed using the Statistical Package for the Social Sciences 20.0 version. The unpaired t-test was used to compare the means between the two groups. The level of significance was set at  $P < 0.05$ .

## Results

The study consisted of 20 dental implants placed in mandibular posterior region, 18 implants were placed in first molar region and 2 were placed in the second molar region.

The age range of participants in Group A was 19–41 years and a mean age of 27.33 years. The age range, in Group B, was 19–45 years with mean age of 31 years [Figure 1]. The smallest dimension of the implant used was 3.3 × 11.5 mm and largest was 4.2 × 13.5 mm.

The mean MBL comparisons between the Groups A and B have not yielded any significant differences ( $P > 0.05$  when compared from the 3<sup>rd</sup>, 6<sup>th</sup>, 9<sup>th</sup>, to 12<sup>th</sup> month) after implant placement [Table 1].

The mean value of PI in Group A was 0.44 at the 3<sup>rd</sup> month, 0.77 at the 6<sup>th</sup> month, 1 at the 9<sup>th</sup> month, and 1.11 at the 12<sup>th</sup> month with a minimum score of 0 and maximum score of 2 signifying overall good oral hygiene maintenance. Likewise, the mean value of PI in Group B was 0.5 at the 3<sup>rd</sup> month, 0.9 at the 6<sup>th</sup> month, 1.2 at the 9<sup>th</sup> month, and 1.3 at the 12<sup>th</sup> month [Figure 2].

The mean value of GI followed similar pattern with a minimum score of 0 and maximum score of 2 signifying only mild gingival inflammation in both the groups over measured 4 timelines [Figure 3].

The mean value of CI in Group A showed 0.11 at the 12<sup>th</sup> month that of Group B was and 0.42. The calculus deposit was not observed in the 3<sup>rd</sup>, 6<sup>th</sup>, and 9<sup>th</sup> months in our sample. The CI thus was signifying good oral hygiene overall in both groups [Figure 4].

## Discussion

Implant dentistry has developed dramatically in the past 30 years. Since the discovery of osseointegration in 1977, the application of dental implants has progressed from being the support of a fixed prosthesis for an edentulous mandible to the sophisticated usage of dental implants in the replacement of single or multiple missing teeth in partially edentulous as well as completely edentulous jaws. The implant success can be gauged based on

**Table 1:** Intergroup comparisons of marginal bone loss in various time intervals

Parameter (month)	Surface	Group A	Group B	P-value
3 <sup>rd</sup>	Mesial	0.31±0.078	0.37±0.094	0.161
	Distal	0.32±0.066	0.38±0.063	0.069
6 <sup>th</sup>	Mesial	0.70±0.086	0.76±0.096	0.174
	Distal	0.72±0.066	0.79±0.066	0.077
9 <sup>th</sup>	Mesial	0.92±0.097	0.96±0.096	0.408
	Distal	0.94±0.113	0.99±0.087	0.337
12 <sup>th</sup>	Mesial	1.13±0.100	1.16±0.108	0.732
	Distal	1.14±0.123	1.19±0.128	0.443

$P < 0.05$  is considered significant; unpaired t-test

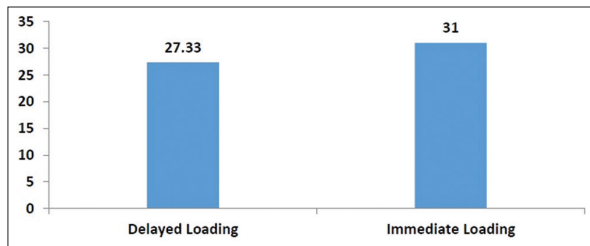


Figure 1: Age distribution between groups of the study

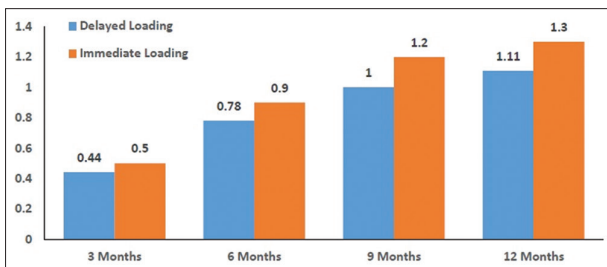


Figure 2: Distribution of plaque index between groups of the study

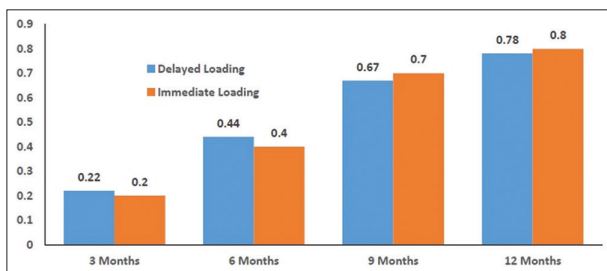


Figure 3: Distribution of gingival index between groups of the study

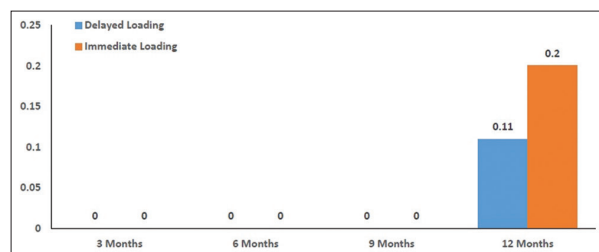


Figure 4: Distribution of calculus index between groups of the study

osseointegration at long-term follow-up with both acceptable bone and soft-tissue attachment level around the implant.

Osseointegration is defined as “contact established without interposition of on-bone tissue between normal remodeled bone and on implant, entailing sustained transfer and distribution of load from the implant to and within bone tissue.”<sup>[12]</sup> The possible reasons for crestal bone loss around implants include relation to dental arch, that is, more in maxilla, more in anterior jaw region, more in low density bone, occlusal overload, microgap at the implant-abutment interface, a polished implant neck, surface type (more in non-hydroxyapatite coated), implant design,

prosthetic abutment material, decreased interimplant distance (being less than 3 mm), surgical technique, second surgical intervention in conventional loading, smoking habits and post-operative antibiotic treatment, systemic causes, and adverse habits.<sup>[12,13]</sup> The criteria for implant success, survival, and failure by International Congress of Oral Implantologists may be used to evaluate the success of dental implants.<sup>[14]</sup>

The current study did not show any significant differences between the groups, implying difference was obtained based on type of loading. The bone loss in Group A seems to be as a result of disuse atrophy caused due to lack of stimulation of peri-implant tissues. Similar results were seen in studies done by Maló *et al.*,<sup>[15]</sup> Guruprasada *et al.*,<sup>[5]</sup> and Kacer *et al.*<sup>[8]</sup> where no statistical difference was observed in terms of peri-implant bone loss between immediate loading and delayed loading. Paradoxical to this are a few studies which reported that the association of peri implant bone loss and implant failure rate is significant. The immediately loaded implants loaded had higher bone loss when compared to those loaded conventionally.<sup>[14,16]</sup>

Guruprasada *et al.* in their study compared peri-implant bone levels of immediate and conventionally loaded implants and reported no significant difference in that the average peri-implant bone loss (after 6 months and 1 year) for immediate or conventional loading (0.69 mm and 1.09 mm). They reported that immediate implant loading protocol has a highly acceptable clinical success rate in partially edentulous lower jaw although implant survival rate is slightly inferior to conventional loading protocol.<sup>[5]</sup> This is in line with findings of the current study. The advanced produces or modifications that are associated with success in this topic were immediate loading of one piece implants using provisional acrylic resin crown with minimally invasive or traumatic, flapless surgery, computer-assisted surgery with the pre-planned immediate restoration, and thermochemical osseointegration after hydroxyapatite coated immediate implant surgery which are reported in recent literature.<sup>[17-19]</sup>

The main lacunae of our study are the duration of follow-up and sample size. Long-term follow-up duration of up to 5–10 years is necessary to predict the exact outcome of the technique and larger sample sizes are required to predict exact outcome of this technique, which can be employed in future studies.

## Conclusion

There were no significant differences in the MBL, GI, PI, and CI between the immediate and conventionally loaded implants in mandibular posterior region. The success of treatment (osseointegration) and complications were similar irrespective of the type of loading and immediate loading can be considered as an alternative to conventional loading in the mandibular posterior region.

## References

1. Abraham CM. A brief historical perspective on dental implants, their surface coatings and treatments. *Open Dent J* 2014;8:50-5.
2. Brånemark PI, Adell R, Albrektsson T, Lekholm U, Lundkvist S,

- Rockler B. Osseointegrated titanium fixtures in the treatment of edentulousness. *Biomaterials* 1983;4:25-8.
3. Adell R, Lekholm U, Rockler BR, Brånemark PI. A 15-year study of osseointegrated implants in the treatment of the edentulous jaw. *Int J Oral Surg* 1981;10:387-416.
  4. Soydan SS, Cubuk S, Oguz Y, Uckan S. Are success and survival rates of early implant placement higher than immediate implant placement? *Int J Oral Maxillofac Surg* 2013;42:511-5.
  5. Guruprasada M, Thapliyal GK, Pawar VR. A comparative analysis of periimplant bone levels of immediate and conventionally loaded implants. *Med J Armed Forces India* 2013;69:41-7.
  6. Chrcanovic BR, Albrektsson T, Wennerberg A. Immediate nonfunctional versus immediate functional loading and dental implant failure rates: A systematic review and meta-analysis. *J Dent* 2014;42:1052-9.
  7. Romanos GE, Aydin E, Locher K, Nentwig GH. Immediate vs. delayed loading in the posterior mandible: A split-mouth study with up to 15 years of follow-up. *Clin Oral Implants Res* 2016;27:e74-9.
  8. Kacer CM, Dyer JD, Kraut RA. Immediate loading of dental implants in the anterior and posterior mandible: A retrospective study of 120 cases. *J Oral Maxillofac Surg* 2010;68:2861-7.
  9. Kim TH, Knezevic A, Jorgensen M, Rich S, Nowzari H. Prospective, 1-year observational study of double-threaded tapered body dental implants with immediate loading. *J Prosthet Dent* 2015;114:46-51.
  10. Engelhardt S, Papacosta P, Rathe F, Özen J, Jansen JA, Junker R. Annual failure rates and marginal bone-level changes of immediate compared to conventional loading of dental implants. A systematic review of the literature and meta-analysis. *Clin Oral Implants Res* 2015;26:671-87.
  11. Lemes HD, Sartori ID, Cardoso LC, Ponzoni D. Behaviour of the buccal crestal bone levels after immediate placement of implants subjected to immediate loading. *Int J Oral Maxillofac Surg* 2015;44:389-94.
  12. Sanz-Sánchez I, Sanz-Martín I, Figuero E, Sanz M. Clinical efficacy of immediate implant loading protocols compared to conventional loading depending on the type of the restoration: A systematic review. *Clin Oral Implants Res* 2015;26:964-82.
  13. Park JH, Kim YK, Yun PY, Yi YJ, Yeo IS, Lee HJ, *et al.* Analysis of factors affecting crestal bone loss around the implants. *J Korean Dent Sci* 2009;3:12-7.
  14. Misch CE, Perel ML, Wang HL, Sammartino G, Galindo-Moreno P, Trisi P, *et al.* Implant success, survival, and failure: The international congress of oral implantologists (ICOI) Pisa consensus conference. *Implant Dent* 2008;17:5-15.
  15. Maló P, de Araújo Nobre M, Lopes A, Ferro A, Gravito I. Single-tooth rehabilitations supported by dental implants used in an immediate-provisionalization protocol: Report on long-term outcome with retrospective follow-up. *Clin Implant Dent Relat Res* 2015;17 Suppl 2:e511-9.
  16. Linares A, Mardas N, Dard M, Donos N. Effect of immediate or delayed loading following immediate placement of implants with a modified surface. *Clin Oral Implants Res* 2011;22:38-46.
  17. Albertini M, Fernandez-Yague M, Lázaro P, Herrero-Climent M, Rios-Santos JV, Bullon P, *et al.* Advances in surfaces and osseointegration in implantology. *Biomimetic surfaces. Med Oral Patol Oral Cir Bucal* 2015;20:259-66.
  18. Rajput N, Siyad KP, Rathinavelu G, Chandrasekaran SC, Mohammed J. Minimally invasive transmucosal insertion and immediate provisionalization of one-piece implant in partially edentulous posterior mandible. *J Clin Diagn Res* 2013;7:2070-3.
  19. Schnitman PA, Hayashi C. Gingival height and bone level in response to computer assisted implant surgery and immediate restoration. *J Oral Implantol* 2015;41:459-66.

**How to cite this article:** Anand GS, Mohammed M, Kumar NM, Vaaka PHD, Palla S. Effectiveness of immediate loading protocol over conventional loading protocol in mandibular posterior region – A comparative prospective clinical study. *J Adv Clin Res Insights* 2020;7(3): 48-52.

This work is licensed under a Creative Commons Attribution 4.0 International License. The images or other third party material in this article are included in the article's Creative Commons license, unless indicated otherwise in the credit line; if the material is not included under the Creative Commons license, users will need to obtain permission from the license holder to reproduce the material. To view a copy of this license, visit <http://creativecommons.org/licenses/by/4.0/> © Anand GS, Mohammed M, Kumar NM, Vaaka PHD, Palla S. 2020